DDH and Clubfoot

CHAPTER 27, PAGES 728-732

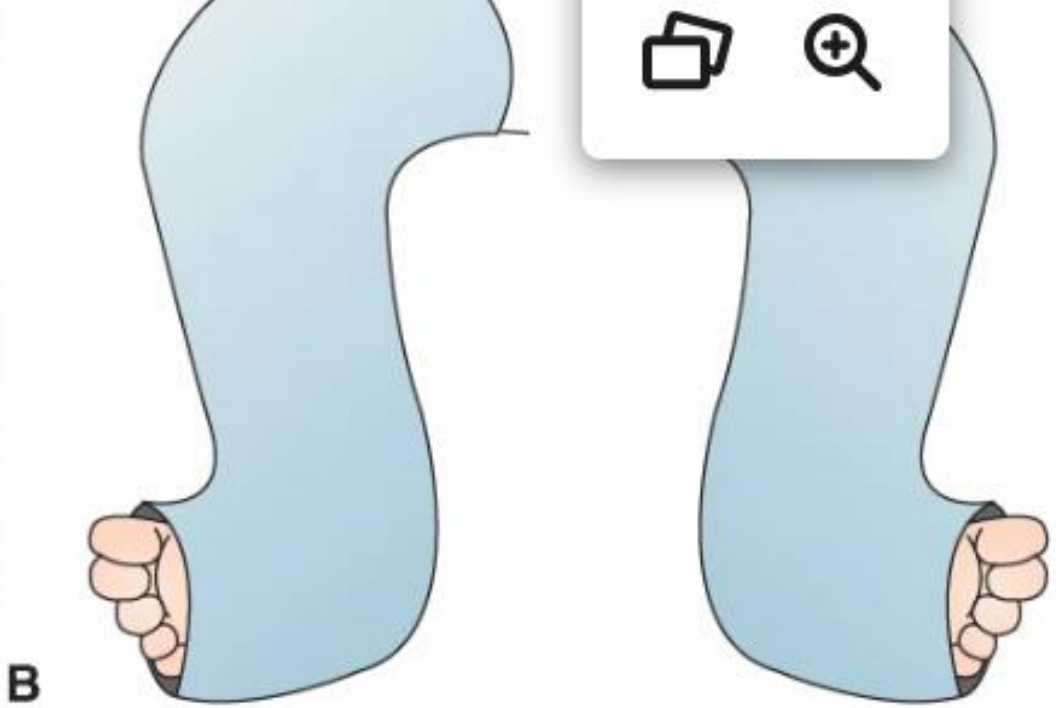

Talipes disorder (clubfoot)

The talipes disorders are ankle–foot disorders, commonly called clubfoot.

Some newborns who appear to have a talipes disorder actually have only an unusual foot position (a pseudotalipes) that developed because of their cramped intrauterine position

In these infants, the foot can be properly aligned by manual manipulation

Clubfoot Assessment

The earlier a true disorder is recognized, the sooner correction can occur.

When performing a newborn assessment, examine the feet for any signs of talipes disorders.

If there are any, inform the pediatric provider who may refer the infant to an orthopedist specialist to begin the process of evaluating the infant and providing monitoring or treatment

Clubfoot Management

Surgical intervention is recommended in the newborn period, around 1 to 2 weeks of age. For correction, a series of five to seven casts are applied to gradually mold the foot into proper alignment over a few months

When the foot is in the correct alignment without manipulation, the infant is fitted for a brace.

- Although the disorder involves the ankle, the cast or brace extends above the knee to ensure a firm correction

Because talipes casts are high on the leg, change diapers frequently to prevent a wet diaper from touching the cast and causing it to become soaked with urine or stool.

Review with parents how to check the infant's toes for coldness or blueness and how to blanch a toenail bed and watch it turn pink to assess for good circulation.

Because a newborn cannot report pain except by generalized crying, parents must evaluate crying episodes in the infant carefully

Clubfoot Management

Infants grow so rapidly in the neonatal period that casts or braces for talipes disorders are adjusted every 1 or 2 weeks

After approximately 6 weeks (the time varies depending on the extent of the problem), the final cast will be removed. Following this, the infant may have to sleep in Denis Browne splints (shoes attached to a metal bar to maintain position) or high-top shoes at night for a few more months to ensure an effective correction.

Parents may need to perform passive foot exercises such as putting the infant's foot and ankle through a full range of motion several times a day for several months.

Full serial casting is primary treatment, surgical correction may be performed if not successful

DDH

Developmental dysplasia of the hip (DDH) (often referred to as congenital hip dysplasia) is improper formation and function of the hip socket and is considered a spectrum of abnormalities affecting the hip joint

DDH is more likely to occur with breech birth, a female infant, and a birthing parent's first pregnancy

Additional risk factors include family history of DDH, oligohydramnios, large birth weight for gestational age, metatarsus adductus, and torticollis

DDH Assessment

All infants should be screened for DDH from birth through 6 to 12 months of age by performing the Ortolani and Barlow maneuver(BOX 27.3)

On inspection, the affected leg may appear slightly shorter than the other because the femur head rides so high in the socket. This is most noticeable when the child is lying supine and the thighs are flexed to a 90-degree angle toward the abdomen, causing one knee to be lower than the other

An unequal number of skin folds may also be present on the posterior thighs

DDH Management

Infants less than 6 months of age are usually treated by using flexion–abduction splinting devices.

Correction of subluxated and dislocated hips involves positioning the hip into a flexed, abducted (externally rotated) position to press the femur head against the acetabulum and cause the acetabulum to deepen its contour from the pressure.

Brace and splints, such as the von Rosen, Pavlik, Craig, or Frejka, may be utilized for treatment of an unstable hip, and patient–family preferences should have a substantial influence on which type is chosen

The Pavlik harness has a high success rate in treating subluxation and reducible DDH.

A small number of children who do not achieve correction by noninvasive methods will have corrective and therapeutic hip surgery, which may involve having a pin inserted to stabilize the hip.

Pavlick Harness

A Pavlik harness is an adjustable chest halter that abducts the legs. It is the method of choice for therapy because it reduces the time interval for therapy to 3 to 4 weeks and simplifies care (Fig. 27.6A).

Soft plastic stirrups (booties) with quick-fastening closures attach to leg extension straps and hold the hips flexed, abducted, and externally rotated. Instruct parents how to lay the infant supine, grasp the infant's thighs, and abduct them to place the femoral head into the acetabulum and then apply the harness.

The harness is then worn under clothing continually except when bathing.

Advise parents to assess the skin under the straps daily for irritation or redness or potential skin breakdown from the harness rubbing.

Caution them also that the harness achieves its effect by gentle continual pressure; it will be ineffective if parents remove it frequently or forget to put it in place.

Pavlick Harness

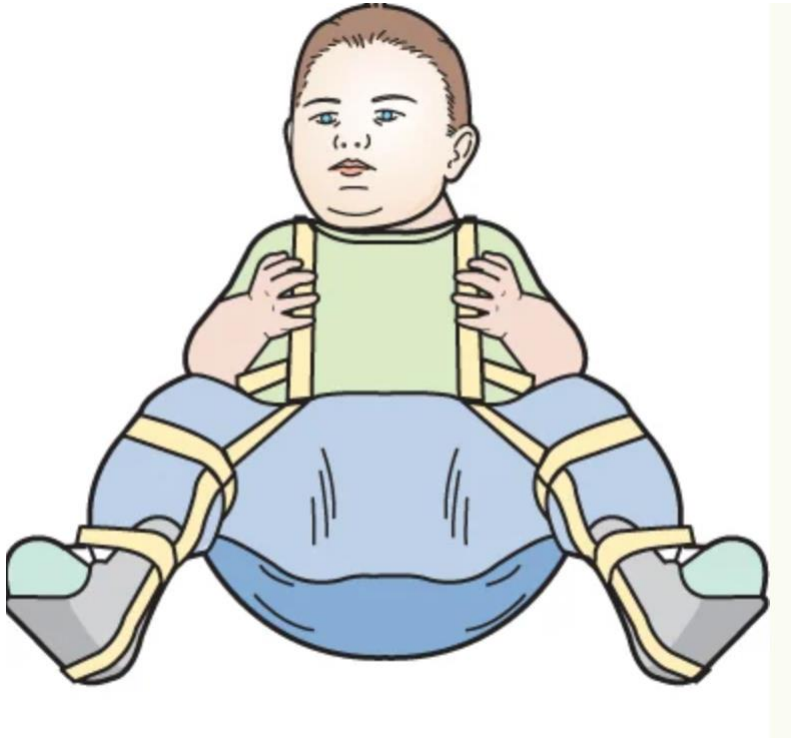

Spica Cast

Be certain that parents have a car seat that can be modified to accommodate a large cast

Teach parents how to do this type of neurovascular assessment (check temperature and circulation in toes) before they take an infant home from the hospital so they can prevent circulatory compression from a rapidly growing leg outgrowing the cast

Spica Cast